

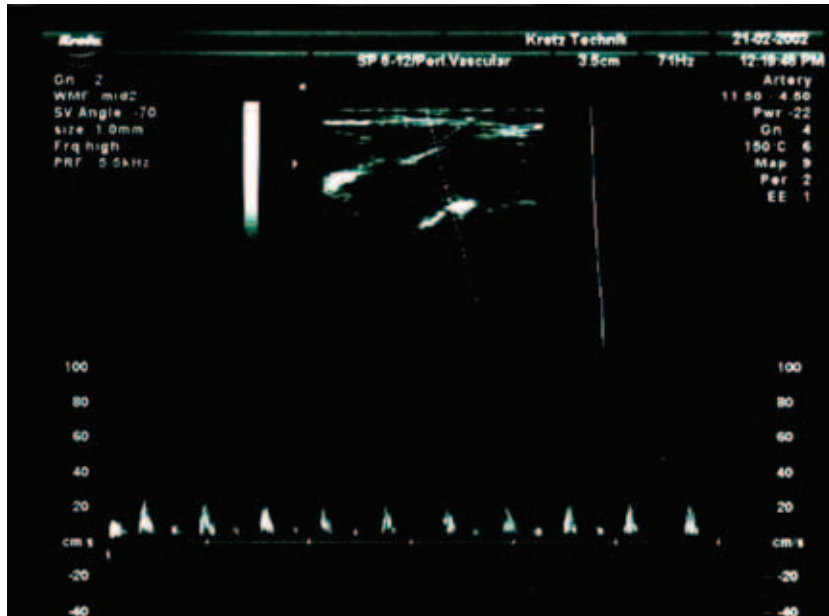Fig. 1 – Doppler ultrasonogram under normal conditions.

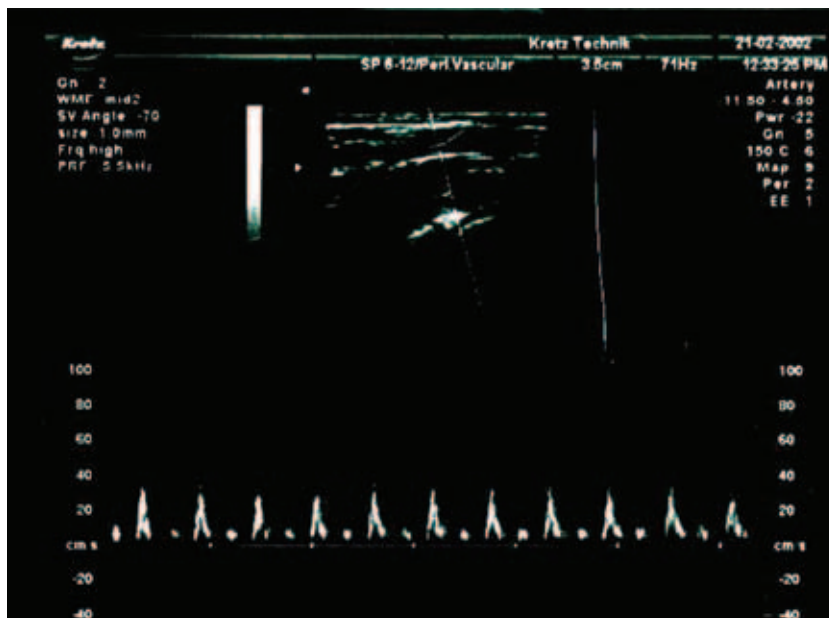


Fig. 2 – Doppler ultrasonogram after 10 minutes exposure to polychromatic radiation.

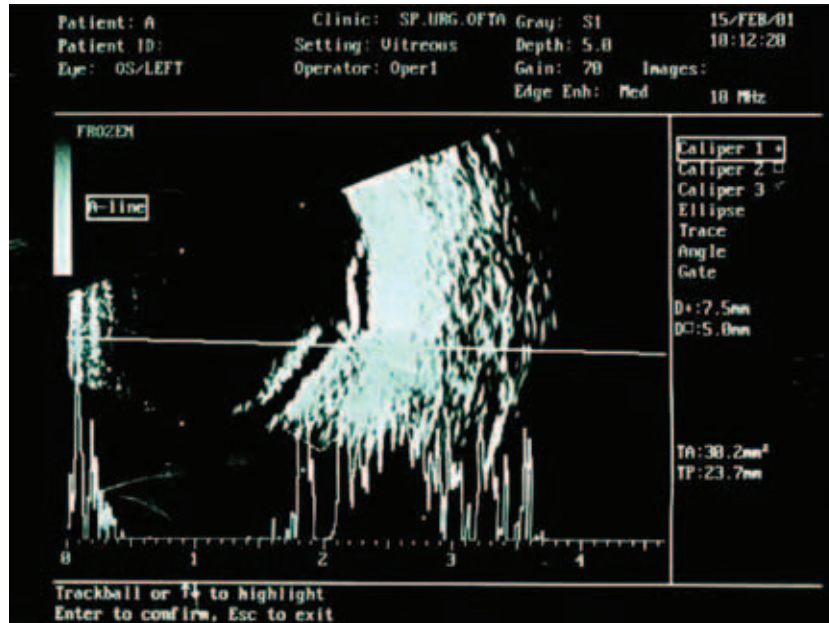


Fig. 4 – Ultrasonography image revealing the initial 7.5/5 mm tumour formation.

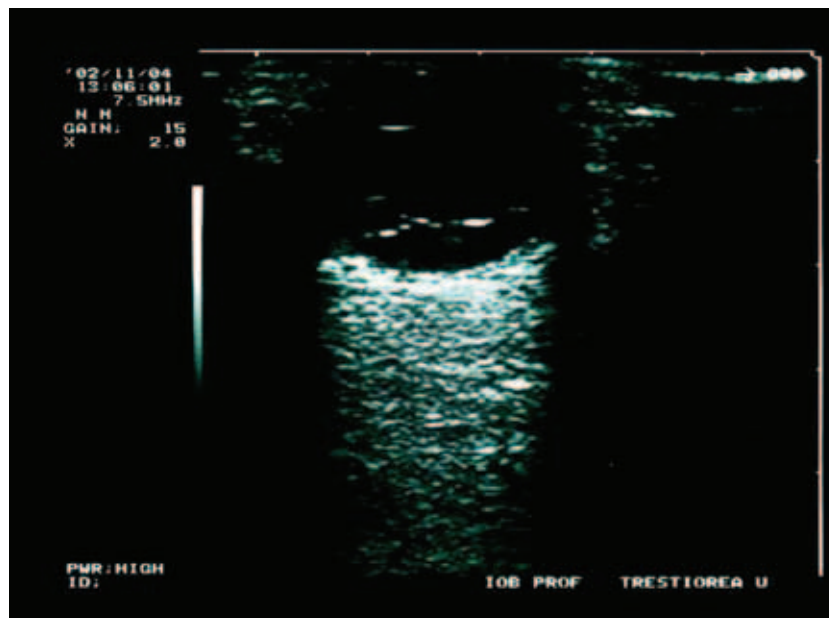


Fig. 5 – Ultrasonography image revealing the tumor-induced retinal detachment.

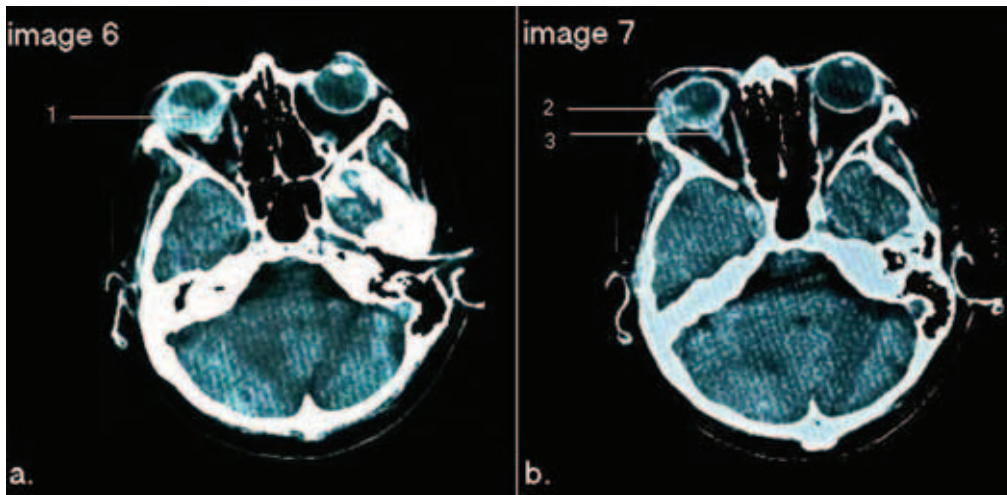


Fig. 6 – The computer tomography examination before starting the photostimulated chemotherapy: sections of interest reveals (1) choroid metastasis; (2) lacrimal gland and (3) optical nerve.

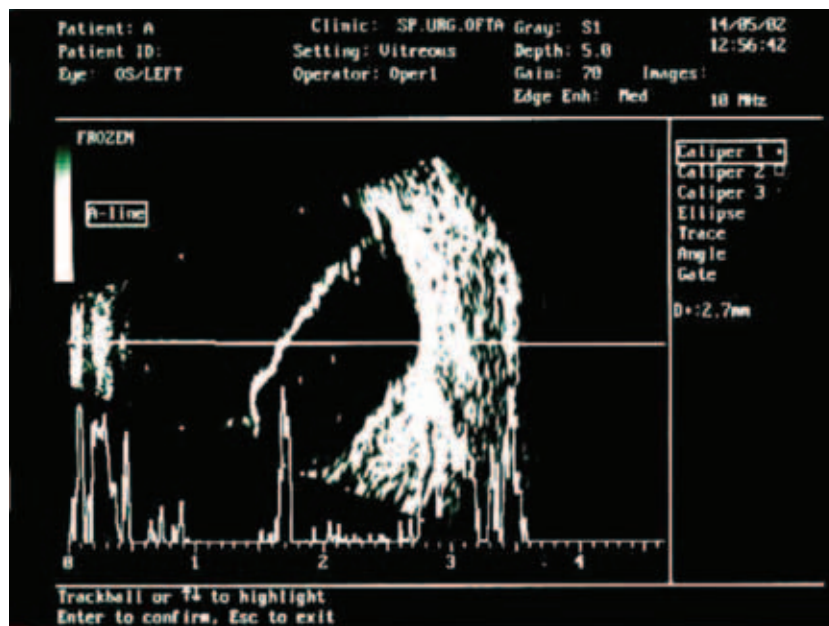


Fig. 7 – Ultrasonography image revealing the radial decrease of the tumor to 2.7 mm after 5 sessions of treatment.

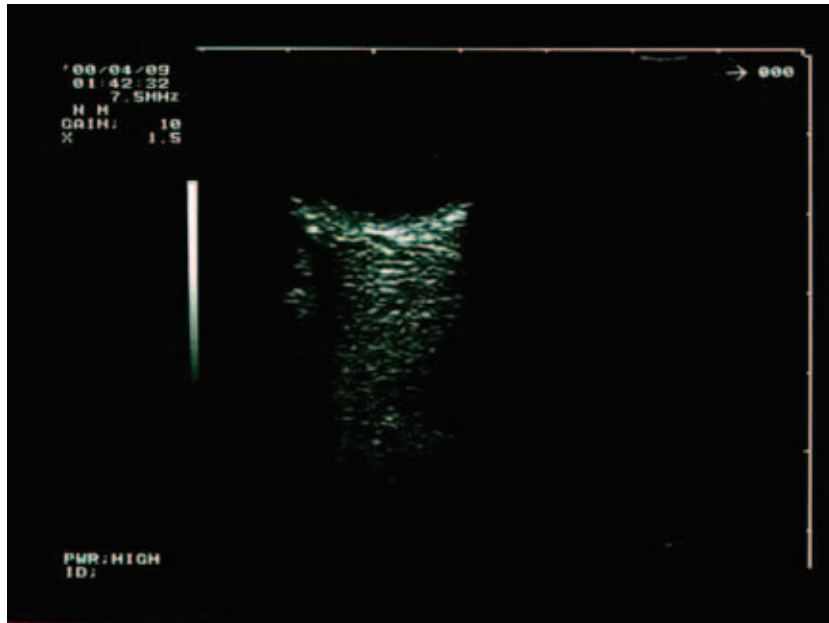


Fig. 8 – Ultrasonography image revealing the retinal attachment after 10 sessions of treatment.

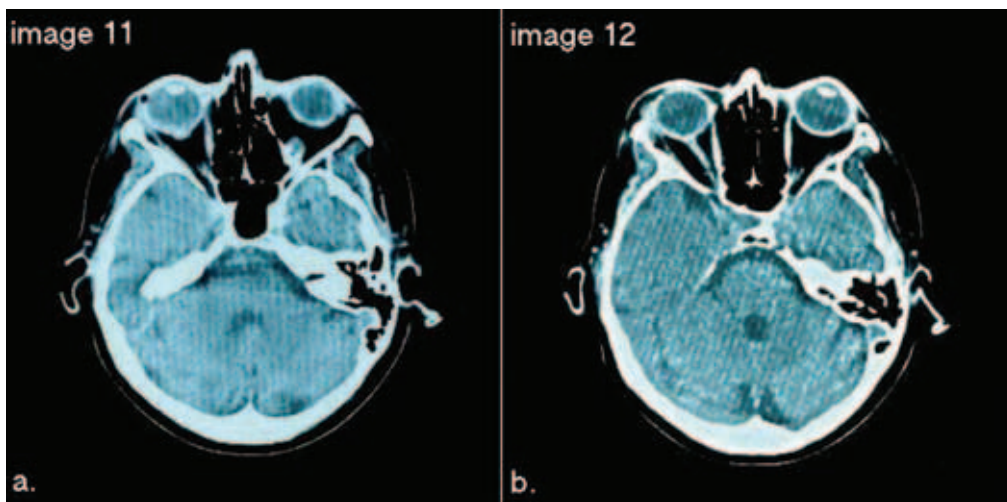


Fig. 9 – The computed tomography examination after 10 sessions of treatment: sections of interest do not reveal any tumor formation at the left eye level, the volumes of the lacrimal gland and optical nerve are normal.