

INCREASE OF CISPLATIN THERAPEUTICAL INDEX THROUGH OPTICAL IRRADIATION: A CASE STUDY OF CHOROIDAL METASTASIS

R. FUMAREL¹, GABRIELA MURGOI¹, P. ALBERT¹, ANCA HURDUC¹, M. L. PASCU²

¹ "Profesor Doctor Alexandru Trestioreanu" Institute of Oncology, Soseaua Fundeni Nr. 252,
Sector 3, Bucharest, E-mail: rfumarel@hotmail.com

² National Institute for Laser, Plasma and Radiation Physics, Laser Department, Str. Atomistilor
Nr. 409, Com Magurele, Jud. Ilfov, 077125, E-mail: mihai.pascu@inflpr.ro

(Received March 3, 2008)

Abstract. The reported study has pursued the increase of the therapeutical index of Cisplatin (cytotoxic agent frequently used in the chemotherapy of choroidal metastases) by exposure of the neoplastic tissue to a radiation emitted by a halogen lamp in spectral range 400–2000 nm. Doppler ultrasonography has shown that, following exposure of the living tissue, the local microvascularization increases notably in a controlled and reversible way. Spectral absorption measurements have shown the lack of interaction of the Cisplatin molecules with the optical radiation. Therefore, the increase in the therapeutical index of this cytotoxic agent may take place by accelerating the intracellular hydrolyze processes ensuring the absorption of near infrared radiation (900–2000 nm) by the water molecules. The use of optical irradiation makes it possible to use Cisplatin doses 10 times lower than in the conventional chemotherapy. That, in turn, generates minimal secondary effects (kidney toxicity) while increasing the antineoplastic effect of the drug.

Key words: Cisplatinum kinetics, photostimulated chemotherapy, photostimulation, therapeutic index, Cisplatinum hydrolysis.

1. INTRODUCTION

In most cases, the choroidal metastases are non-symptomatic; they are discovered during the last stages of evolution. Therefore, the response to conventional methods of treatment, like radiotherapy and chemotherapy is, usually, inefficient. For this reason, in the ophthalmological praxis, they frequently resort to enucleation.

The frequency of intraocular metastases at patients with various forms of primary cancer is approximately 12%, but in the case of patients with breast adenocarcinoma it increases to 37% [1, 2].

The most efficient methods of conventional treatment of choroidal metastases are external radiotherapy (proton external beam radiotherapy) using a total standard

dose of 30–40 Gy, distributed in 10–15 fractions, followed by beta or gamma brachytherapy with ^{60}Co , ^{192}Ir or ^{106}Ru (applied only to singular metastases) and metabolic radiotherapy with ^{131}I , employed in the cases generated by the primary tumors of the thyroid [3–5].

Generally, the chemotherapy has not evidenced standard methods or relevant statistics in the treatment of intraocular metastases. However, there are some positive results in this direction, Cisplatin being one of the most efficient cytotoxic agents used to this purpose [6].

A possible unconventional new method applicable in the treatment of this kind of metastases is the Photodynamic Therapy (PDT). The technique makes use of the fact that some photosensitizers administered systemically locate themselves preferentially in the neoplastic tissues and can be subsequently activated by energy transfer from an external optical source, generating in turn active molecular species (*e.g.* $^1\text{O}_2$). They destroy the intracellular targets for which the photosensitizer has a higher tropism. There have been reported studies regarding the age related neovascularization destruction using Verteporfin (VEGF) and optical radiation emitted at 689 nm [7].

Starting from literature reports regarding the results of the conventional chemotherapy with Cisplatin and of the physical bases of PDT action and tissue photostimulation, in this paper a new method of treatment of the choroidal metastases is proposed based on two complementary interaction hypotheses of the optical radiation with the drug/tissue pair:

- Exposure to the visible and near-infrared (VIS-NIR) optical radiation increases the metabolism and local hypervascularization and induces consequently, a higher retention of the cytotoxic agent (systemically administered) in the targeted neoplastic tissue.
- The molecules of Cisplatin can be photoactivated by assisting the hydrolysis process that results from excitation of vibrational levels of the water molecule in the spectral range of 1–2 μm , following the absorption of infrared radiation by the water molecules.

Cisplatin is an inorganic compound containing a platinum atom surrounded in plane by 2 anions of chloride and 2 amino groups in *cis* position [8]. In aqueous solutions containing less than 0.2% NaCl, the Cisplatin molecules hydrolyze by detaching the chloride anions and substituting them with water molecules. The stability of Cisplatin in aqueous solutions becomes high if concentration of chloride ions is higher than 0.9% [9]. Thus, the hydrolysis process takes place in the intracellular environment where the chloride anions are present in much lower concentrations (~ 3 –20 mM) as compared to the bloodstream (~ 100 mM) where the cytotoxic agent is administered. Hydrolysis can be further pushed-up if water molecules involved in the process are excited to higher vibrational levels by absorption of optical radiation emitted in the NIR spectral range.

To verify the above mentioned hypotheses, measurements were made to evidence the photostimulation phenomenon induced by the VIS-NIR radiation; on the other hand the spectral properties of Cisplatin were measured. Based on the obtained results, a Photostimulated Cisplatin Cytostatic Chemotherapy type method was developed leading to a total remission when applied to a case of choroidal metastasis.

2. METHODS

The source of optical radiation is a halogen lamp and the beam parameters are the following:

- emission spectral range: 400 nm–2 μ m; emission is spectrally quasi-continuous;
- color temperature: approximately 2600 K;
- spot energy density/minute: 2.4 J/cm²
- polarization index: > 95%
- specific power density: 40 mW/cm².

The experiments were performed in two distinct stages, one trying to determine the effects of the VIS-IR optical radiation on the living tissues (A) and the other aiming to evidence the optical absorption properties of Cisplatin in the respective spectral range (B):

A. The main effect was the appearance of local hypervascularization following the exposure to optical radiation which was determined by successive Doppler ultrasonography measurements of the anatomical area under study, both in normal conditions and after its exposure to radiation.

B. Aqueous solutions of Cisplatin in natural saline 0.9% having a concentration of 10⁻⁵ M and a neutral pH (6.4) were prepared. The absorption spectra of Cisplatin in these solutions were measured between 400 nm and 900 nm.

It is known from literature reports that after systemic administration of the Cisplatin by “in bolus” injection (1–3 min) or by rapid perfusion (~ 10 min), the maximum plasmatic concentration of the cytotoxic agent appears immediately and is followed by a slow clearance [9]. This leads to the idea that the optical irradiation of the neoplastic tissue must be made practically during the administration of Cisplatin.

The therapeutic protocol itself consists of i.v. administration by rapid perfusion (10–15 min) of 10mg/cm² of Cisplatin diluted in 250 ml natural saline 0.9% simultaneously with optical irradiation of the whole front eyeball. Before administering the cytotoxic agent, the patient is submitted to a forced hydration with 500ml natural saline 0.9% and with 500ml glucose 5%. Post-therapeutically, 250ml mannitol is administered for attenuation of renal toxicity of Cisplatin.

To demonstrate the effectiveness of such a technique, a case study was made on a 48 years old female patient. The anamnesis evidenced radical mastectomy of the left breast for which the histopathological examination revealed a weakly differentiated G3 carcinoma without metastases in 2 axilar lymph nodes. The patient comes back after 7 years with a suspicion of a left eye choroidal metastasis confirmed by the following investigations:

- Left-eye ultrasonography which reveals a hyperechogenic formation with a deep choroidal excavation associated with retina detachment.
- High contrast computer tomography (CT) which does not show alterations of the eye ball but evidences the posterior detachment of retina accompanied by a 0.3 cm wide hematoma.
- Angiofluorography of the central retinal artery which shows the presence of a non-homogeneous infero-papillar mass with precocious and progressive impregnation.
- In this case, having the agreement of the female patient one has decided to apply 10 sessions of Photostimulated Cytostatic Chemotherapy with Cisplatin in the sequence one per week as an alternative to the enucleation.

3. RESULTS AND DISCUSSION

The physiological effect of the VIS-NIR optical radiation on the living tissue can be measurably evidenced by a reversible increase in the local bloodstream speed and temperature in the anatomical area exposed to the radiation flux. This is a consequence of the metabolism acceleration at intracellular level following the interaction between the optical quanta and the cell organites – particularly mitochondria.

The photostimulation is produced when a random tissue area is exposed to the optical radiation emitted at fixed wavelengths or in a continuous spectral range from 400–900 nm. The phenomenon can be evidenced using Doppler ultrasonography by performing successive measurements of the local blood stream speed, both under normal conditions and after irradiation. In Fig. 1 a Doppler ultrasonogram of a cubital arterial segment under normal conditions is shown; similar measurements made after polychromatic irradiation of the adjacent tissue for 10 min is shown in Fig. 2 where it may be seen that after the interaction with light, the blood stream in the arterial segment increases sensibly.

As a consequence, it is obvious that simple irradiation of a neoplastic tissue in the VIS-NIR spectral ranges is counter indicated due to the risk to trigger secondary lesions (metastasis) appearance. Nevertheless, if neoplasm exposure is associated with systemic administration of a cytotoxic agent (Cisplatin, for instance), the photostimulation will favor its retention in the irradiated area as a

consequence of local hypervascularization. On the other hand, the increased ratio of systolic alterations as compared to the diastolic ones determines the prevalence of therapeutic effect as opposed to the side-effect. Based on these measurements, as well as on the fact that the concentration of Cisplatin in blood becomes maximum immediately after rapid perfusion, it is presumed that simultaneous administration of drug and irradiation of the neoplasm will lead mainly to a rapid increase of the intra-tumor tropism of the antineoplastic agent. Simultaneously, intratumorally, interaction phenomena of the light quanta at the molecular level takes place which can influence the way in which the Cisplatin works.

Absorption of the optical radiation by Cisplatin molecules was measured in the 200–900 nm spectral range; the absorption spectrum of a 10^{-5} M Cisplatin solution in natural saline 0.9% at pH = 6.4 was acquired (Fig. 3).

According to these measurements correlated with literature reports about NIR and Fourier transform (FTIR) spectroscopy measurements it results that the Cisplatin molecules do not significantly absorb between 400 nm–2 μ m in which optical source used in the experiments emits: the absorption bands of Cisplatin are located in UVB (250–350 nm) and far infrared between $3400\text{--}3200\text{ cm}^{-1}$ (amino group characteristic stretching band), $1600\text{--}1500\text{ cm}^{-1}$ (amino group asymmetric bending) and $1300\text{--}1200\text{ cm}^{-1}$ (amino group symmetric bending) [10–12]. On the

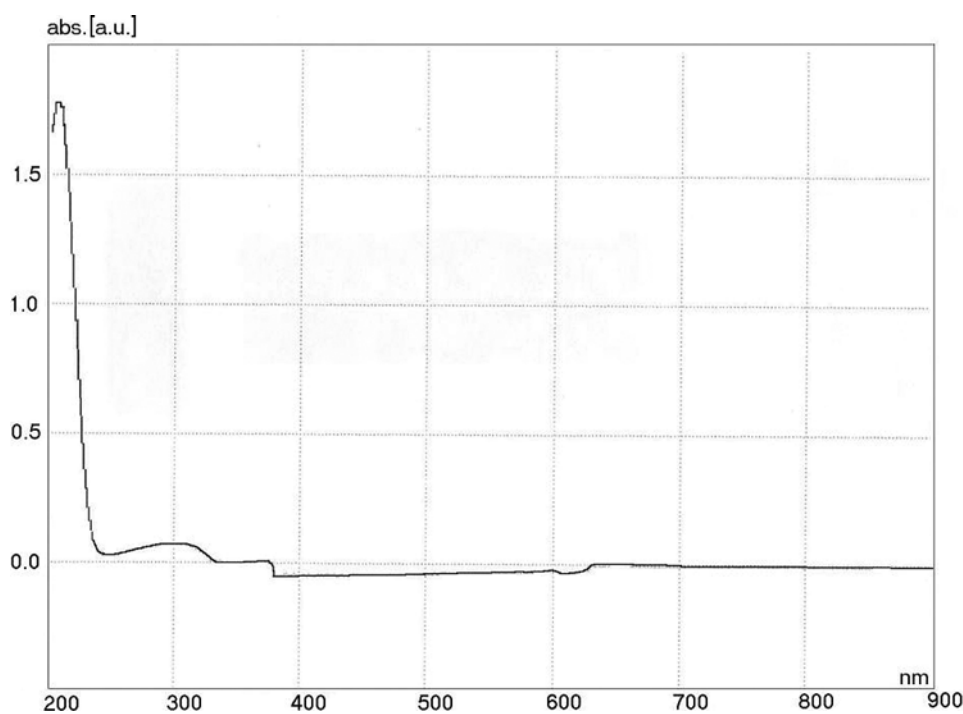


Fig. 3 – UV-VIS absorption spectrum of 10^{-5} M Cisplatin in 0.9% natural saline at pH 6.4.

other hand, the water molecules absorb in the spectral range 1–2 μm at: 970 nm, 1.27 μm , 1.47 μm and 1.9 μm , the excitation of the water molecules in this case being made on the vibrational levels associated to the fundamental electronic state [13]. The combined vibrations involve symmetric (ν_1) and asymmetric stretching (ν_3) and bending (ν_2), according to the assignment given in Table 1 [14].

Table 1

Assignment of VIS NIR vibrational absorption spectrum of liquid water

WAVELENGTH	cm^{-1}	ASSIGNMENT
514 nm	19.460	$av_1 + bv_3; a + b = 6$
606 nm	16.500	$av_1 + bv_3; a + b = 5$
660 nm	15.150	$av_1 + \nu_2 + bv_3; a + b = 4$
739 nm	13.530	$av_1 + bv_3; a + b = 4$
836 nm	11.960	$av_1 + \nu_2 + bv_3; a + b = 3$
970 nm	10.310	$av_1 + bv_3; a + b = 3$
1.27 μm	8.330	$av_1 + \nu_2 + bv_3; a + b = 2$
1.47 μm	6.800	$av_1 + bv_3; a + b = 2$
1.9 μm	5.260	$av_1 + \nu_2 + bv_3; a + b = 1$

Thus, the utilized optical radiation facilitates by its infrared component the intracellular hydrolysis processes of the Cisplatin molecules (essential for the antineoplastic effect) because of the vibrational excitation of the cytoplasmatic water; this leads finally to the increase in the therapeutical index of the cytotoxic agent.

Considering both the effect of photostimulation as well as the facilitation of hydrolysis of Cisplatin molecules induced by the VIS-NIR optical radiation the effectiveness of Photostimulated Cisplatin Cytostatic Chemotherapy technique was tested on a case study; the effects obtained were monitored using ultrasonography and CT.

The initial ultrasonograms of the female patient revealed the existence of a tumor formation of approx 7.5/5 mm in the left eye (Fig. 4) accompanied by the detachment of retina induced by the intraocular metastasis (Fig. 5).

The computer tomography examination through the relevant sections shows the presence of a choroidal metastasis accompanied by the increase in volume of the lachrymal gland and thickening of the optical nerve (Fig. 6).

After five sessions of Photostimulated Cisplatin Cytostatic Chemotherapy an ultrasonogram of the left eye was performed showing the decrease in the radial dimension of the tumor formation from 5 to 2.7 mm (Fig. 7).

At the end of the 10 sessions of treatment (one session per week), both the ultrasonographic and the computer tomography were repeated. The ultrasonographic image showed complete reattachment of retina (Fig. 8) and the relevant sections of the computer tomography examination showed tumor remission and

decrease in volume of the lacrimal gland, accompanied by a normal aspect of the optical nerve (Fig. 9).

The increase of the therapeutic index of Cisplatin due to the reported technique implies maximization of the antineoplastic effect along with minimization of the unwanted side-effects. The main side-effect of Cisplatin consists in its high renal toxicity and it is obvious that for reducing it, the reduction as low as possible of the administered dose is necessary, without altering its cytotoxic effect.

This can be done by optical irradiation of the tumor in the spectral range 400 nm–2 μ m. The utilized halogen lamp provides the increased retention of the cytotoxic agent in the tumor mass by photostimulation (400–900 nm) and facilitates at the same time the hydrolysis of Cisplatin molecules by vibrational excitation of the intracellular water (900 nm – 2 μ m).

The obtained results show that in order to obtain the same therapeutic effect, the needed Cisplatin dose is approximately 10 times lower than in the case in which exposure to optical radiation is not used when delivered systemically (i.v. 10mg/m² as compared to 80–100 mg/m² standard dose) and the side-effect decreases proportionally.

4. CONCLUSIONS

To explain the role of the light in combination with Cisplatin in tumor remission one should be mentioned that it has a relatively low therapeutic index and it does not work intracellularly-wise unless a hydrolysis is done; it does not show absorption bands within 400nm and 2 μ m spectral range..

The method is, however, limited to treating the quasi-external malignant tumors because it requires the exposure of the neoplastic tissue to light radiation in the presence of the cytotoxic agent.

On the other hand, an increase of the number of case studies in the same conditions is needed to investigate the reproducibility of the efficiency of this treatment on a larger number of patients.

Acknowledgements. The authors would like to thank dr. Ruxandra Pascu from the Clinics of Ophthalmology of the University Emergency Hospital Bucharest (SUUB) for helpful discussions in interpreting the obtained results.

REFERENCES

1. R. S. Bloch, S. Gartner, *The incidence of ocular metastatic carcinoma*, Arch. Ophthalmol., **85**, 673–675 (1971).
2. B. Elliasi-Rad, D. M. Albert, W. R. Green, *Frequency of ocular metastases in patients dying of cancer in eye bank populations*, Br J Ophtalmol., **80**, 125–128 (1996).

3. J. Hoogenhout, H. M. A. Brink, A. M. Verbeek *et al.*, *Radiotherapy of choroidal metastases*, *Strahlenther Onkol.*, **165**, 375–379 (1989).
4. E. Minatel, M. G. Trovo, L. Forner *et al.*, *The efficacy of radiotherapy in the treatment of intraocular metastases*, *Br J Radiol.*, **66**, 699–702 (1993).
5. I. Anteby, J. Pe'er, B. Uziely *et al.*, *Thyroid carcinoma metastasis to the choroid responding to systemic ¹³¹I therapy*, *Am J Ophthalmol.*, **113**, 461–462 (1992).
6. J. T. Fan, R. G. Ortiz, H. Buettner, *Regression of choroidal metastases from a bronchial carcinoid tumor after chemotherapy with cisplatin and etoposide*, *Am. J. Ophthalmol.*, **117**, 111–113 (1994).
7. E. S. Gragoudas, A. P. Adamis, E. T. Cunningham Jr. *et al.*, *For the VEGF Inhibition Study in Ocular Neovascularization Clinical Trial Group. Pegaptanib for Neovascular Age-Related Macular Degeneration*, *N. Engl. J. Med.*, **351**, 2805–2816 (2004).
8. M. Rozenzweig, D. D. Von Hoff, M. Slavik *et al.*, *Cis-Dichlorodiammineplatinum (II): A New anticancer drug*, *Ann Intern Med.*, **86**, 803–812 (1977).
9. R. Nagai, R. Okuda, M. Kinoshita *et al.*, *Decomposition Kinetics of Cisplatin in Human Biological Fluids*, *Journal of Pharmacy and Pharmacology*, **48**, 918–924 (1996).
10. Y. Xiaoliang, R. A. Geimhart, *Cisplatin delivery from poly (acrylic acid co-methyl methacrylate) microparticles*, *Journal of Controlled Release*, **106**, 198–208 (2005).
11. H. H. Patterson *et al.*, *Inorg Chem.*, **20**, 2297–2300 (1981).
12. D.S. Martin Jr. *et al.*, *Inorg Chem.* **9**, 1276 (1970).
13. H. Büning-Pfaue, *Analysis of water in food by near infrared spectroscopy*, *Food Chemistry*, **82**, 107–115 (2003).
14. * * <http://www.lsbu.ac.uk/water/vibrat.html>; 3 (2008).